

The autonomic and behavioral profile of emotional dysregulation

J.D. Woolley, BS; M.L. Gorno-Tempini, MD, PhD*; K. Werner, BS*; K.P. Rankin, PhD; P. Ekman, PhD; R.W. Levenson, PhD; and B.L. Miller, MD

Abstract—The authors describe a patient with focal brain atrophy and emotional lability characterized by episodes of excessive crying and laughing. The patient was selectively impaired in the production of voluntary complex facial movements and was unable to regulate her emotional behavior and autonomic reactivity. She also displayed increased behavioral and autonomic changes when explicitly trying to suppress her responses to emotional stimuli (compared with when not trying to regulate her responses). This pattern of deficits supports a selective deficit in voluntary emotional control.

NEUROLOGY 2004;63:1740–1743

Human emotions help coordinate responses to evolutionarily relevant prototypic scenarios, such as threat.¹ Emotions are associated with specific autonomic profiles² and stereotyped facial expressions that are recognized by members of all cultures³ and are produced even by congenitally blind infants.⁴ Attempts to voluntarily suppress emotional displays affect the magnitude of behavioral and autonomic responses to the emotional stimuli.^{5,6} Although issues of lateralization remain unclear, the prefrontal cortex has repeatedly been implicated in voluntary emotion regulation.^{7–9} The mechanisms that produce coordinated multisystem emotional responses can be disrupted, as seen in emotional dysregulation associated with bipolar disorder, schizophrenia, and frontotemporal dementia. New psychological and autonomic tools recently have been developed to study emotional responses in normal individuals. We have adapted these techniques to quantify the emotional deficits in a patient with neurodegenerative disease and symptoms of emotional lability.

Case report. The patient is a 69-year-old woman who was examined for a 5-year history of slowly progressing mutism and emotional lability. Using structural MRI and PET, we identified specific regions of cortical atrophy and hypometabolism. In particular, these imaging studies demonstrated significant (left greater than right) inferior frontal gyrus damage (figure 1). On examination, she had focal deficits in the ability to follow commands to produce or to imitate complex oral-buccal movements (buccofacial apraxia) and a complete inability to speak. Other cognitive do-

mains, including language comprehension, memory, recognition of emotion from faces and prosodic cues, and semantic knowledge of emotion, were remarkably preserved (see E-Methods and tables E-1 and E-2 on the *Neurology* Web site at www.neurology.org). Her presentation suggested a syndrome of focal cortical atrophy caused by a neurodegenerative disease, possibly cortical basal degeneration.

To quantify the patient's emotional deficits, we assessed her motor and autonomic responses to disgust-eliciting films (war surgeries and burn-victim treatments) and sudden unexpected noises (acoustic startle). Unlike other negative emotions that produce marked increases in cardiac activation, such as fear and anger, disgust typically produces only moderate changes (often small decreases), likely reflecting vagal influence on this emotional response.² When normal subjects are asked to suppress the behavioral signs of emotion in response to a disgusting film, they exhibit sharply *diminished* behavioral signs of disgust and sharp *increases* in cardiovascular activation.⁵

While watching a disgusting film and not instructed to modulate expressive behavior (“Non Suppress”), the patient's expressive behavior and cardiac physiologic responses were comparable with control subjects (figure 2). However, when asked to hide her feelings while watching another disgusting film (“Suppress”), she showed significantly *more* expressive behavior (shaking her head and silently mouthing the word “terrible”) and a significant *decrease* in cardiac response vs control subjects. The patient reported that she had tried to suppress her response, indicating that she had understood the instructions; she stated that she had been moderately successful.

The patient's responses to acoustic startle stimuli were also atypical. When this noxious stimulus is presented without warning, it produces marked increases in cardiovascular activation and large behavioral responses.⁵ If control subjects are told when the startle stimulus will occur, however, they “brace” themselves, and the behavioral response is significantly reduced, and the cardiovascular response is increased.⁶ The patient's behavioral responses to the warned startle were *increased* when compared with her responses to the unwarned startle. She also demonstrated *decreased* cardiovascular activation when warned.

To assess our patient's voluntary control of facial movement, we conducted a number of tests. Using the Facial Action Coding System, we assessed her ability to make individual facial move-

Additional material related to this article can be found on the *Neurology* Web site. Go to www.neurology.org and scroll down the Table of Contents for the November 9 issue to find the link for this article.

*These authors contributed equally to this work.

From the Department of Neurology (Drs. Gorno-Tempini, Rankin, and Miller, J.D. Woolley), University of California, San Francisco; Department of Psychology (Dr. Levenson, K. Werner), University of California, Berkeley; and Human Interaction Laboratory (Dr. Ekman), University of California, San Francisco, CA.

Supported by the following grants: NIA grants P50-AG05142, AG16570, AG 19724-FTD PPG, and ADRC AG023501.

Received January 13, 2004. Accepted in final form July 1, 2004.

Address correspondence and reprint requests to Dr. B.L. Miller, Department of Neurology, University of California San Francisco, 350 Parnassus Street, Suite 706, San Francisco, CA 94143-1207; e-mail: bmiller@memory.ucsf.edu

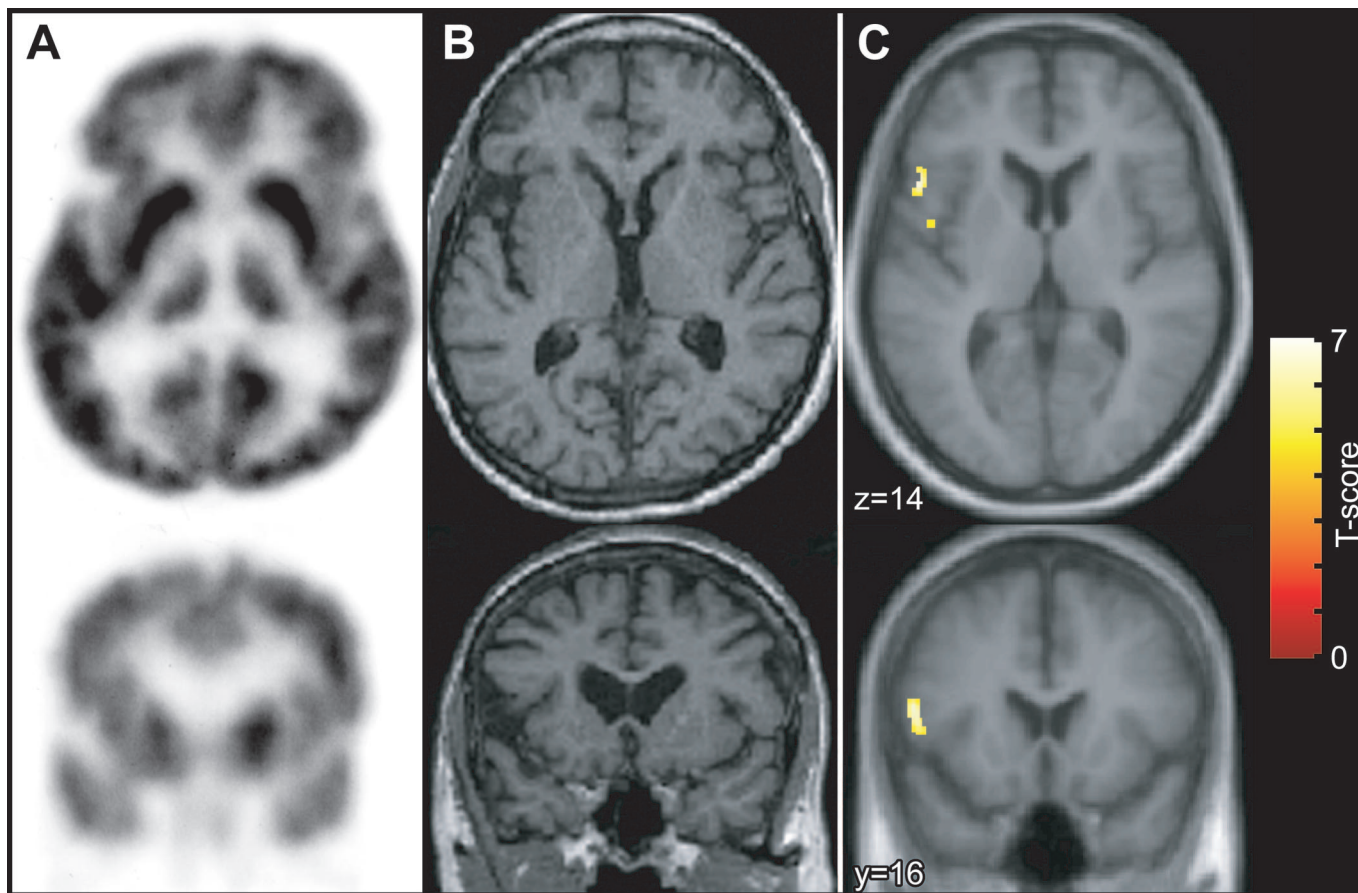


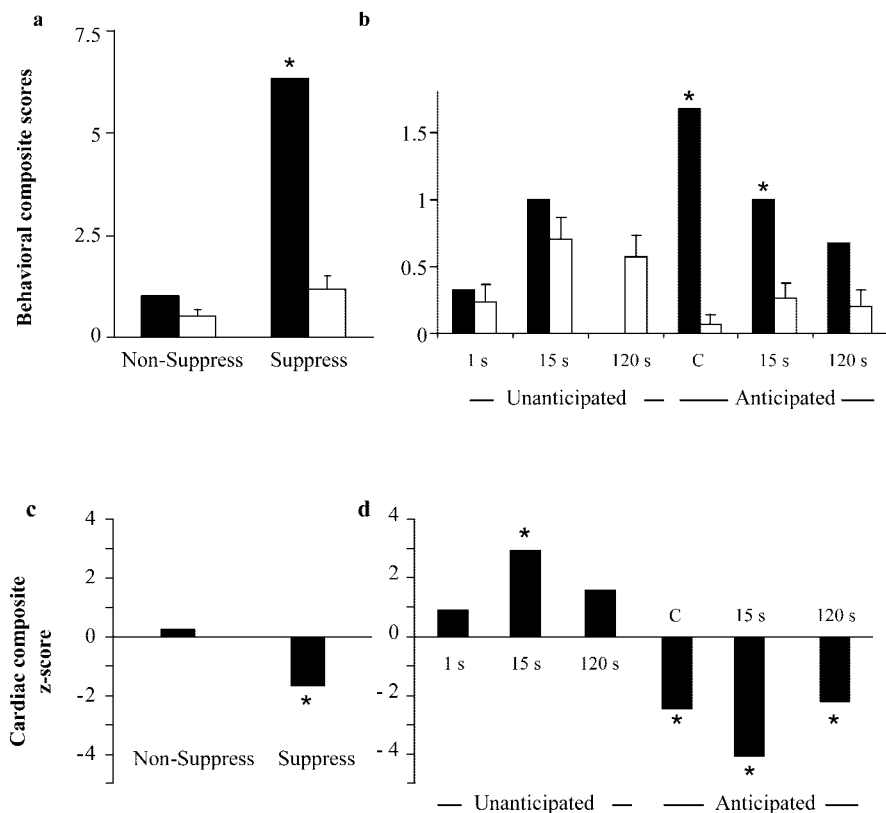
Figure 1. The patient has selective damage of the left inferior frontal gyrus. The 18-fluorodeoxyglucose PET (A) and T1-weighted MPRAGE MRI (B) axial and coronal sections through the head of the caudate nucleus show inferior frontal (left greater than right) hypometabolism (PET) and atrophy (MRI). (C) Voxel-based morphometry (VBM) statistical analysis of the patient's whole brain MRI volumes compared with 21 control subjects (see E-Methods on the Neurology Web site) showing areas of significant gray matter loss superimposed on axial and coronal sections of the mean of the control brain. The left inferior frontal gyrus ($x = -54$, $y = 16$, $z = 14$; $Z = 4.9$; BA = 44/6) was the only area significantly atrophied in the patient ($p < 0.05$ corrected for multiple comparisons). The right inferior frontal gyrus ($x = 54$, $y = 33$, $z = -3$; $Z = 3.8$; BA = 44) showed less volume loss ($p < 0.001$ uncorrected for multiple comparisons).

ments singly and in pairs (see table E-3 on the *Neurology* Web site). She was able to make many small simple facial movements, including opening and closing her eyes and moving her eyebrows, but was unable to combine two or more single movements into more complex movements. Tests of facial praxis revealed a similar inability to produce complex facial movements. The patient was unable to pretend to puff on a pipe, suck on a straw, or smoke a cigarette to command or to imitation. Her facial performance improved when the actions were not requested by command. For example, she was able to suck on a real straw appropriately, display happy expressions when told a joke, and display sad expressions during her many bouts of crying during the assessment (figure 3). On physical examination and praxis testing, arm movements were slightly impaired, whereas leg and trunk movements were normal.

Discussion. Our findings reveal that this patient had widespread abnormalities in the coordination of behavioral, autonomic, and motor responses to emotional stimuli. She was able to react appropriately on an involuntary basis, but her voluntary direction of emotional behavior was impaired. Notably, although the patient demonstrated volitional control of simple movements, she was not able to control many com-

plex behaviors, including making complex facial movements and producing or imitating familiar oral-buccal movements. It appears that her attempts to reduce her behavioral reactions to the disgust film and to the anticipated startle resulted in a paradoxical increase in behavioral reactions and decrease in cardiovascular activation. Because we did not specifically assess the patient's ability to regulate her responses to nonemotional stimuli, her deficits might relate to deranged voluntary response suppression in general and not specifically to emotional dysregulation.

Although the prefrontal cortex has repeatedly been shown to be involved in voluntary control of emotion, the relative role of the two hemispheres remains unclear. In a study of the effects of stroke on spontaneous nonverbal expression by Ross et al.,¹⁰ patients with left-sided cortical damage showed increased expressiveness compared with control subjects, whereas patients with right-sided lesions



*Figure 2. Effects of voluntary control on emotional responses. (A) Behavioral responses (average of mouth, body, and face movement) of the patient (black bars) and control subjects (white bars) for two disgust films. In the “Non-Suppress” condition, subjects were simply asked to watch the film. In the “Suppress” condition, subjects were instructed to suppress outward displays of emotion during the film. (B) Behavioral responses before and after two separate startles caused by bursts of white noise. In the “Unanticipated” condition, responses were collected before (data not shown), 1, 15, and 120 seconds after an uncued acoustic startle. In the “Anticipated” condition, a visual 20-second countdown cued subjects to the upcoming noise stimulus. Responses were collected before the warning (data not shown), during the countdown (“C”), and 15 and 120 seconds after the startle. (C) The patient’s composite cardiovascular response (cardiac interbeat interval, systolic and diastolic blood pressures) during two disgust films in the “Non-Suppress” condition and the “Suppress” condition. Bars denote averaged Z scores of the patient’s cardiac responses to emotional stimuli relative to control subjects (mean control response is 0). (D) The patient’s composite cardiovascular response before and after two separate startles caused by bursts of white noise (*Z score, >1.60). The patient’s baseline behavioral and cardiac values were not significantly different from those of control subjects (see E-Methods on the Neurology Web site).*

aged Z scores of the patient’s cardiac responses to emotional stimuli relative to control subjects (mean control response is 0). (D) The patient’s composite cardiovascular response before and after two separate startles caused by bursts of white noise (*Z score, >1.60). The patient’s baseline behavioral and cardiac values were not significantly different from those of control subjects (see E-Methods on the Neurology Web site).

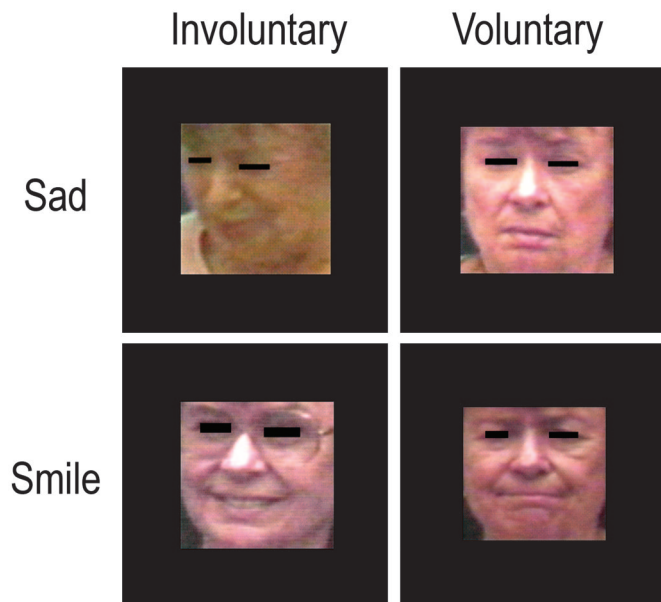


Figure 3. The patient is unable to make emotional faces voluntarily. Images on the left are voluntary attempts to pose sad (top) and happy (bottom) faces. Images on right were taken when the patient spontaneously cried (top) and laughed at her husband’s joke (bottom).

showed decreased expressiveness compared with control subjects. The authors hypothesized that the right cerebral hemisphere mediated nonverbal expression of emotion, whereas the left hemisphere played an inhibitory role on expressivity.¹⁰ Consistent with this view, a recent functional neuroimaging study showed that when subjects were asked to cognitively reappraise highly negative scenes in non-emotional terms, there was increased activation of the left lateral and medial prefrontal cortices as compared with when subjects were asked to merely observe similar scenes.⁷ Another study showed a more bilateral pattern of frontal activations, including the right superior frontal gyrus and the right anterior cingulate gyrus,⁹ when men attempted to voluntarily inhibit sexual arousal to erotic film clips. The authors also noted significant activation of the left inferior frontal cortex in this condition. A third study⁸ found activations only in the right prefrontal cortex when subjects were asked to suppress their responses to sad films. When our patient’s MRI scan was compared with scans obtained from 21 normal age- and sex-matched control subjects using voxel-based morphometry, the left inferior frontal gyrus was the area that showed the most significant volume loss. This result supports the idea that this region may be involved in emotional regulation.

However, the often-seen bilateral brain involvement in neurodegenerative disease precludes strong conclusions about lateralization.

Although many of the patient's impairments were emotional, her emotional knowledge was intact, indicating that her inappropriate emotional behavior was not because of a lack of understanding. Her deficits in the ability to control her behavior intentionally and her unusual patterns of cardiovascular response may underlie her inability to regulate her emotional behavior outside of the laboratory, as manifested by her frequent emotional outbursts and general emotional lability. This case underscores the degree of independence of neural networks subserving voluntary emotional control, involuntary emotion production, and emotional understanding, and suggests that neural circuits in the lateral prefrontal cortex are important for voluntary emotional regulation.

References

1. Levenson RW. Autonomic specificity and emotion. In: Davidson RJ, Scherer KR, Goldsmith HH, eds. *Handbook of affective sciences*. New York: Oxford University Press, 2003:212–224.
2. Ekman P, Levenson RW, Friesen WV. Autonomic nervous system activity distinguishes among emotions. *Science* 1983;221:1208–1210.
3. Ekman P, Friesen WV, O'Sullivan M, et al. Universals and cultural differences in the judgments of facial expressions of emotion. *J Pers Soc Psychol* 1987;53:712–717.
4. Galati D, Scherer KR, Ricci-Bitti PE. Voluntary facial expression of emotion: comparing congenitally blind with normally sighted encoders. *J Pers Soc Psychol* 1997;73:1363–1379.
5. Gross JJ, Levenson RW. Emotional suppression: physiology, self-report, and expressive behavior. *J Pers Soc Psychol* 1993;64:970–986.
6. Gross JJ, Levenson RW. Hiding feelings: the acute effects of inhibiting negative and positive emotion. *J Abnorm Psychol* 1997;106:95–103.
7. Ochsner KN, Bunge SA, Gross JJ, Gabrieli JD. Rethinking feelings: an fMRI study of the cognitive regulation of emotion. *J Cogn Neurosci* 2002;14:1215–1229.
8. Levesque J, Eugene F, Joanette Y, et al. Neural circuitry underlying voluntary suppression of sadness. *Biol Psychiatry* 2003;53:502–510.
9. Beauregard M, Levesque J, Bourgouin P. Neural correlates of conscious self-regulation of emotion. *J Neurosci* 2001;21:RC165.
10. Ross EDH, Richard W, Buck R. Differential hemispheric lateralization of primary and social emotions: implications for developing a comprehensive neurology for emotions, repression, and the subconscious. *Neuropsychiatry Neuropsychol Behav Neurol* 1994;7:1–19.

MARK YOUR CALENDARS!

AAN 57th Annual Meeting in Miami Beach
April 9–April 16, 2005
Miami Beach, FL

The 57th Annual Meeting Scientific Program highlights leading research on the most critical issues facing neurologists. More than 1,000 poster and platform presentations cover the spectrum of neurology—from updates on the latest diagnostic and treatment techniques to prevention and practice management strategies.

For more information contact AAN Member Services at memberservices@aan.com; (800) 879-1960, or (651) 695-2717 (international).